

Ninety babies born after round spermatid injection into oocytes: survey of their development from fertilization to 2 years of age

Atsushi Tanaka, M.D., Ph.D.,^a Kohta Suzuki, M.D., Ph.D., M.P.H.,^b Motoi Nagayoshi, M.D.,^a Akihiro Tanaka, M.B.I.T.,^a Youichi Takemoto,^a Seiji Watanabe, Ph.D.,^c Satoru Takeda, M.D., Ph.D.,^d Minoru Irahara, M.D., Ph.D.,^e Naoaki Kuji, M.D., Ph.D.,^f Zentarō Yamagata, M.D., Ph.D.,^g and Ryuzo Yanagimachi, Ph.D.^h

^a Saint Mother Obstetrics and Gynecology Clinic and Institute for Assisted Reproductive Technologies, Fukuoka, Japan;

^b Department of Health and Psychosocial Medicine, Aichi Medical University School of Medicine, Aichi, Japan;

^c Department of Anatomic Science, Hirosaki University Graduate School of Medicine, Hirosaki, Japan; ^d Department of Obstetrics and Gynecology, Juntendo University School of Medicine, Tokyo, Japan; ^e Department of Obstetrics and Gynecology, Institute of Biomedical Sciences, Tokushima University Graduate School, Tokushima, Japan; ^f Department of Obstetrics and Gynecology, Tokyo Medical College, Tokyo, Japan; ^g Basic Science for Clinical Medicine, Division of Medicine, Graduate School Department of Interdisciplinary Research, University of Yamanashi, Yamanashi, Japan; and

^h University of Hawaii Medical School, Honolulu, Hawaii

Objective: To compare physical and cognitive development of babies born after round spermatid injection (ROSI) with those born after natural conception.

Design: Comparison of efficiencies of ROSI and ICSI using testicular spermatozoa, performed in the St. Mother Clinic. Physical and cognitive development of ROSI babies recorded by parents in the government-issued Mother-Child Handbook was checked and verified by attending pediatricians. Data included baby's weight gain and response to parents' voice/gesture.

Setting: Assisted reproduction technology practice.

Patient(s): A total of 721 men participated in ROSI; 90 ROSI babies were followed for 2 years for their physical and cognitive development. Control subjects were 1,818 naturally born babies.

Intervention(s): Surgical retrieval of spermatogenic cells from testes; selection and injection of round spermatids into oocytes; oocyte activation, in vitro culture of fertilized eggs, and embryo transfer to mothers.

Main Outcome Measure(s): Physical and cognitive development of ROSI babies (e.g., body weight increase, response to parents, and understanding and speaking simple language) compared with naturally born babies.

Result(s): Of 90 ROSI babies, three had congenital aberrations at birth, which corrected spontaneously (ventricular septa) or after surgery (cleft lip and omphalocele). Physical and cognitive development of ROSI babies was similar to those of naturally born babies.

Conclusion(s): There were no significant differences between ROSI and naturally conceived babies in either physical or cognitive development during the first 2 years after birth.

Clinical Trial Registration Number: UMIN Clinical Trials Registry UMIN000006117. (Fertil Steril® 2018;110:443–51. Copyright © 2018 The Authors. Published by Elsevier Inc. on behalf of the American Society for Reproductive Medicine. This is an open access article under the CC BY-NC-ND license (<http://creativecommons.org/licenses/by-nc-nd/4.0/>)).

El resumen está disponible en Español al final del artículo.

Key Words: Assisted fertilization, human egg, physical and cognitive development, round spermatid injection

Discuss: You can discuss this article with its authors and other readers at <https://www.fertsterdialog.com/users/16110-fertility-and-sterility/posts/32485-25452>

Received December 13, 2017; revised April 9, 2018; accepted April 24, 2018.

Atsushi T. has nothing to disclose. K.S. has nothing to disclose. M.M. has nothing to disclose. Akihiro T. has nothing to disclose. Y.T. has nothing to disclose. S.W. has nothing to disclose. S.T. has nothing to disclose. M.I. has nothing to disclose. N.K. has nothing to disclose. Z.Y. has nothing to disclose. R.Y. has nothing to disclose.

A.T. and K.S. should be considered similar in author order.

Reprint requests: Atsushi Tanaka, M.D., Ph.D., Saint Mother Obstetrics and Gynecology Clinic, 4–9-12 Orio Yahatanishi-ku Kitakyushu, Fukuoka, Japan (E-mail: incho@stmother.com).

Fertility and Sterility® Vol. 110, No. 3, August 2018 0015-0282

Copyright © 2018 The Authors. Published by Elsevier Inc. on behalf of the American Society for Reproductive Medicine. This is an open access article under the CC BY-NC-ND license (<http://creativecommons.org/licenses/by-nc-nd/4.0/>).

<https://doi.org/10.1016/j.fertnstert.2018.04.033>

Round spermatids are haploid male germ cells at the stage immediately before their transformation into tail-bearing spermatozoa. After live offspring were born following the introduction of round spermatids into mouse oocytes (1), Edwards et al. (2) proposed the use of round spermatids as substitutes for mature spermatozoa for some infertile men who are unable to produce spermatozoa. The process is referred to as round spermatid injection (ROSI). Although the birth of several ROSI babies was reported by Tesarik et al. (3) and others (4, 5), some investigators questioned the value of ROSI owing to its low efficiency (6–8).

Subsequently, since the Practice Committee of the American Society for Reproductive Medicine (9) considered ROSI to be an experimental rather than a recommended practice, clinicians' interest in ROSI quickly faded. We nevertheless continued our endeavor to improve ROSI technique and reported the birth of 14 healthy babies in 2015 (10).

The key to our success was careful selection of presumptive round spermatids based on their morphologic and physical characteristics. Here, we report fertilization rates, the preimplantation development of ROSI-generated embryos, and the physical and cognitive development of 90 babies born after ROSI compared with babies conceived naturally. These 90 ROSI babies include the 14 babies previously reported (10).

MATERIALS AND METHODS

Ethical Aspects

ROSI was conducted at the Saint Mother Obstetrics and Gynecology Clinic with the informed consents of all participating patients. The Institutional Review Board of the Saint Mother Obstetrics and Gynecology Clinic approved ROSI on Dec, 20, 2009. ROSI was registered and adhered to International Committee of Medical Journal Editors criteria. The University Hospital Medical Information Network Clinical Trial Registry number was UMIN000006117.

Subjects

This study reports the outcome of 2,657 ROSI interventions performed in the St. Mother Obstetrics and Gynecology Clinic from September 2011 to December 2014, culminating in the birth of 90 babies from 83 couples, including the 14 babies whose developmental details were partly reported previously (10). All of the men, including 12 whose testicular status (Johnsen score) and ROSI results were reported previously (10), were diagnosed as azoospermic after semen and microscopic testicular sperm extraction (Micro-TESE) analyses in the St. Mother Clinic as well as other clinics that the male patients previously visited. They were 25–47 years of age (mean 33.7 ± 4.9), and all except one had high blood FSH (27.6 ± 14.5 IU/mL). The mean age of their wives was 33.7 ± 4.1 years (range 23–43).

Steps Before ROSI and the ROSI Procedure

Whenever ours or other clinics found that a male patient was totally azoospermic after examination of several semen samples, we performed palpitation of testicles as well as measurements of FSH and T levels. Based on these parameters, we

could differentiate men with obstructive azoospermia from those with nonobstructive azoospermia with >90% accuracy (11, 12). Obstructive azoospermic men have swollen and hard epididymides and normal values of FSH. From these men, concentrated and motile spermatozoa suitable for ICSI could be collected. Men with high FSH level and soft small testicles, indications of nonobstructive azoospermia, were candidates for testicular sperm extraction (Micro-TESE). The procedures of TESE and ROSI were reported in detail previously (10). We collected seminiferous tubules not only from the surface of testis, but also from deep inside of the testis, first looking for normal-looking spermatozoa.

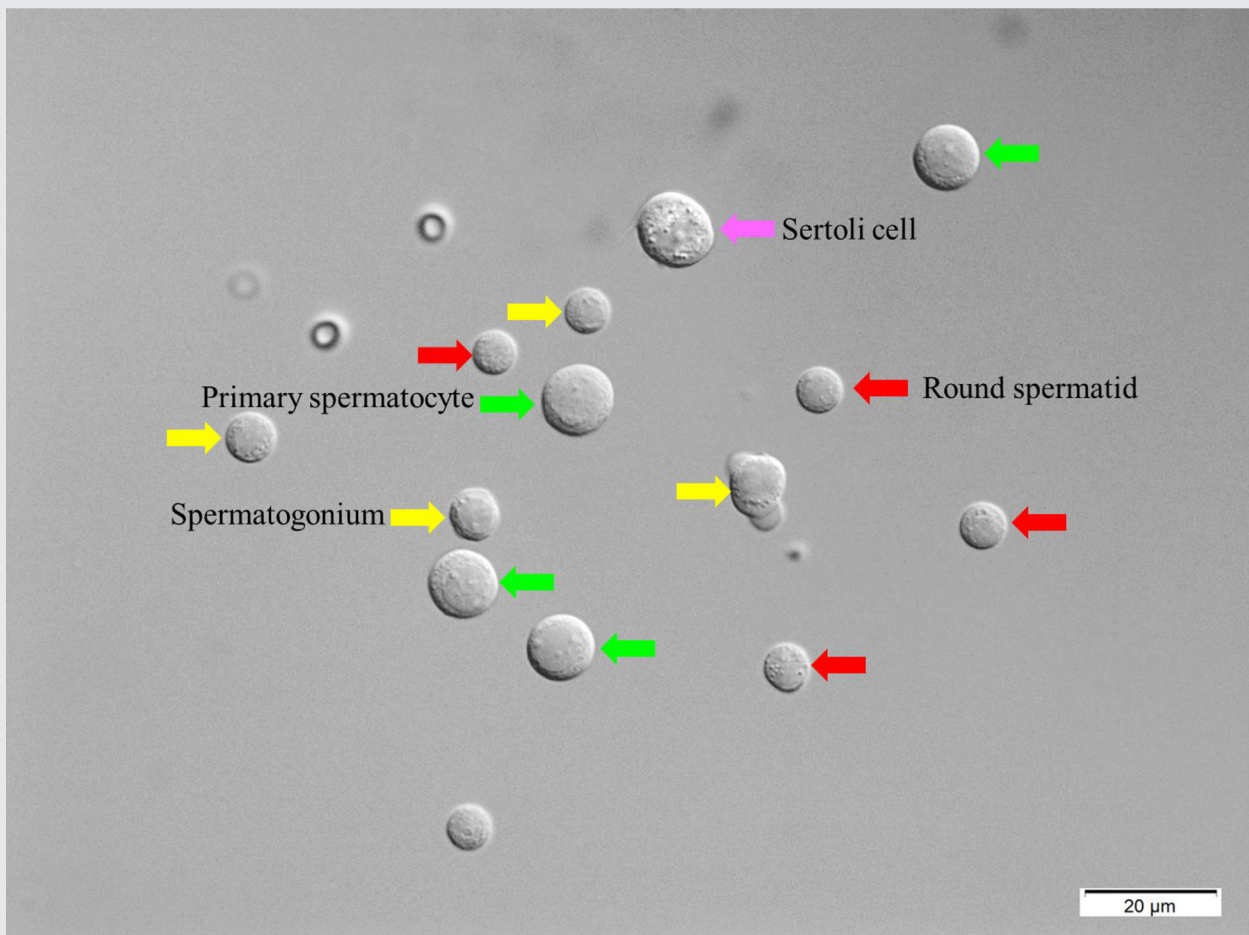
When biopsied samples contained normal-headed motile spermatozoa, we used them for ICSI, regardless of their motility intensity. When none of them showed motility, not even twitching, we performed a hypo-osmolality test, a live/dead sperm staining test, and exposure to 3.6 mmol/L pentoxifylline (13) to see if they were alive. Normal-headed spermatozoa were preferentially used for ICSI. We also used spermatozoa with round heads, megaloh-heads, elongated heads, and even slightly deformed heads as well as normal- and nearly-normal-looking elongated spermatids.

When none of above were found after an intensive search, yet the men had normal-looking round spermatids, we presented to the couples the choices of ROSI treatment, sperm donation, or adoption. Even though we stressed the low success rate of ROSI, 95% of couples desired to try ROSI first. Details of ROSI, cryopreservation of ROSI embryos before transfer to mothers and assessment of pregnancy 4–5 weeks after transfer, were previously published by Tanaka et al. (10). ROSI procedures starting from collection of testicular cells, identification of round spermatids, and injection of a spermatid into an egg are shown in [Supplemental Video 1](#) (available online at www.fertstert.org) of the present paper.

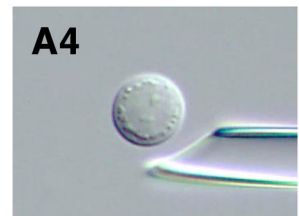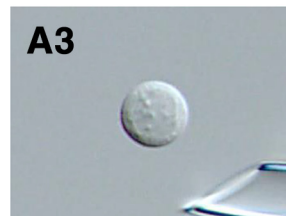
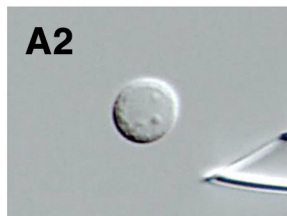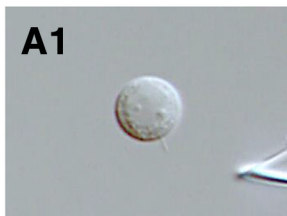
[Figure 1](#) shows various cell types seen after maceration of testicular cells of an azoospermic man. Large Sertoli cells and large primary spermatocytes could be readily identified. Smaller spermatogonia and round spermatids may be difficult to distinguish from each other, even though round spermatids had a slightly higher nucleus-cytoplasm ratio than spermatogonia. Unlike spermatids, some spermatogonia had pseudopodia (10).

We could visually distinguish spermatogonia from spermatids by the presence or absence of nucleoli within the nucleus ([Fig. 1](#)). Some somatic cells may look like spermatogenic cells, but we could easily distinguish them from germ cells by aspirating them into a micropipette. When a spermatid is sucked in and out of the pipette, its plasma membrane is disrupted and the nucleus appears as a clear homogeneous sphere ([Fig. 2A](#)). A similarly treated spermatogonium also has disrupted plasma membrane but its nucleus has one or, more commonly, a few nucleoli ([Fig. 2B](#)). In contrast, the plasma membranes of somatic cells could not be disrupted readily ([Fig. 2C](#)). [Supplemental Video 1](#) shows how we collected and macerated seminiferous tubes, identified round spermatids, and electrostimulated and injected round spermatids into the oocytes.

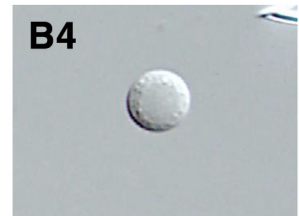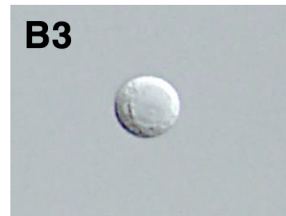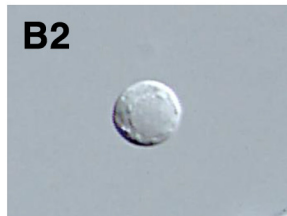
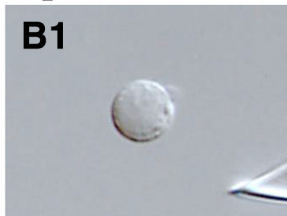Pregnancy care and deliveries were performed at hospitals in the patients' own residential areas, and congenital

FIGURE 1

Spermatogonium

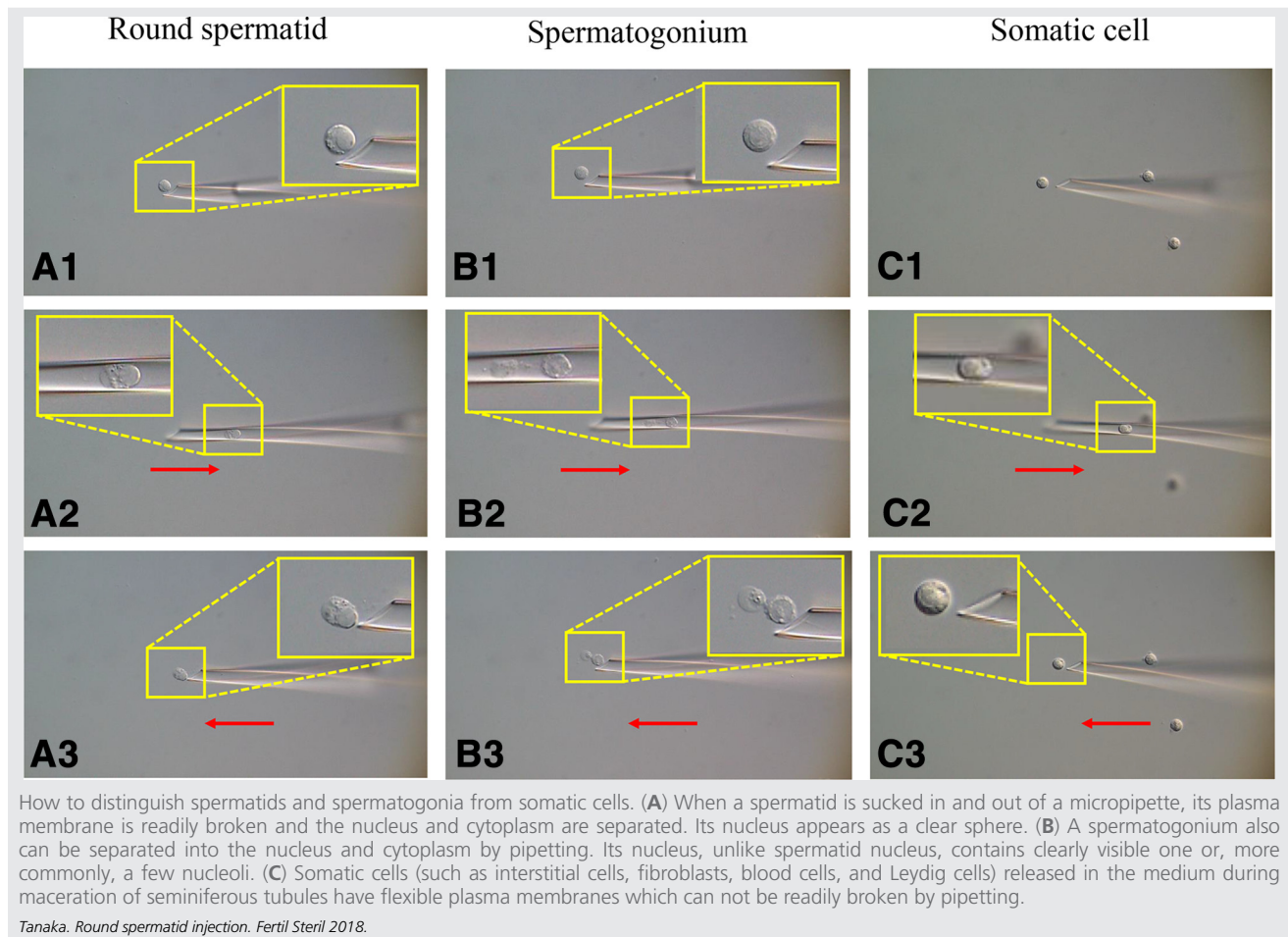


Spermatid



Testicular cells after mechanical maceration of seminiferous tubules followed by treatment with collagenase and DNase: Sertoli cell (purple arrow); round spermatids (red arrows); spermatogonia (yellow arrows), and primary spermatocytes (green arrows). Photographed under an interference-contrast microscope. The nucleus of a spermatogonium (A1–A4) has one or, more commonly, a few nucleoli within the nucleus, whereas that of spermatid (B1–B4) does not.

Tanaka. Round spermatid injection. *Fertil Steril* 2018.

FIGURE 2

aberrations in newborns, if any, were recorded by the attending physicians.

Follow-Up of Physical and Cognitive Development of Infants

Data on ROSI babies were gathered by the St. Mother Obstetrics and Gynecology Clinic and those of naturally born babies by Seibo Hospital. All ROSI babies reported here were born from September 2011 to December 2014 in clinics in various parts of Japan. Anthropometric data of the natural babies was collected as a part of an ongoing research project funded by the Japan Agency for Medical Research and Development.

In Japan, all mothers receive a Boshi Kenko Techo (Maternal and Child Health Handbook) which is distributed through local governments (14). This handbook, given to all pregnant women free of charge when they register their pregnancy, instructs parents to keep records of the mothers during pregnancy, delivery, and post-delivery period, as well as the physical and cognitive states of infants/babies. Information recorded by parents in the handbook was checked and verified by attending pediatricians. The value of this book for the objective

screening and early detection of children's disorders and abnormalities by physicians has already been established (15). For the present study, questionnaires were prepared referring to a paper published in Japan (16) and sent to parents. Questions concerned maternal history of pregnancy and delivery, fertility treatment (only in the case of the "natural" group), gestational week at birth, the number of the reported pregnancy, sex of the child/children, weight and height at birth and at the ages of 1.0, 1.5, and 2.0 years, and motor and cognitive functions. Information recorded in the book had been checked and verified by attending pediatricians. Because St. Mother Clinic, like most other Japanese clinics that specialize in assisted reproduction, does not perform pregnancy care and delivery services, anthropometric data of naturally born babies were obtained through the Seibo Clinic (Shinjuku, Tokyo), one of the clinics in Japan with some of the highest and most active pregnancy care and delivery services.

In Japan any aberrations (medical, physical, mental, social) found in children born after assisted reproductive technology (ART) treatments are to be reported by attending physicians to the central office of the Japan Society of Obstetrics and Gynecology.

Data Analysis

In the analysis of physical growth of infants, study factors and the outcomes were, respectively, the method of conception (ROSI or natural conception) and anthropometric data (body weight, height, and body mass index at birth and 12, 18, and 24 months of age). Multiple linear regression models were used to assess the growth of ROSI infants. Variables of parity, gestational weeks, sex, and multiple births were used as covariates.

In analysis of the cognitive capacity and physical growth of infants, the method of conception (ROSI or natural) was the study factor. To assess cognitive capacity, the following binary questions were used: Does the baby display any gesture in response to greeting such as hello and goodbye? (12 months of age, question 1); Does the baby move his/her body happily when he/she hears music from radio or television? (12 months of age, question 2); 3) Does the baby understand simple commands such as “come” and “give me”? (12 months of age, question 3); 4) Can the baby utter recognizable words such as “mama” and/or “booboo”? (18 months of age, question 4).

Multiple logistic regression models were constructed with the variables of parity, gestational week at birth, sex, multiple birth, age in days at each check-up, and birth weight as covariates. The analyses without multiple births were used as sensitivity analyses. All analyses were conducted with the use of SAS version of 9.34 (SAS Institute).

RESULTS

We performed ROSI when testicular spermatozoa or elongated spermatids judged to be suitable for ICSI were not found in TESE samples. As presented in Table 1, fertilization and cleavage rates of ROSI oocytes were significantly higher than those of TESE-ICSI oocytes ($P < .001$ and $P < .001$, respectively), but the live birth rate after ROSI was considerably lower than that after TESE-ICSI ($P < .001$). It should be noted that the delivery rate was higher in both ROSI and TESE-ICSI groups ($P < .001$ and $P < .001$, respectively) when transferred embryos had been kept frozen before transfer.

A total of 90 babies (55 male and 35 female) were born to 83 women; 76 women delivered singletons once, six had twins after embryo transfer, and one had two ROSI babies 2 years apart. Three (3.3%) of the 90 ROSI babies had congenital abnormalities at birth: one cleft lip, one ventricular septal defect (VSD), and one omphalocele. The cleft lip was corrected surgically at 6 months after birth and the VSD closed spontaneously within 1 year. The omphalocele was 1.5 cm in diameter and the length of extending intestine was 1 cm. A second operation at 6 months after birth was necessary to resuture the initial incision. This baby is developing normally with no chromosomal aberrations. Cytogenetic analyses of 53 aborted ROSI fetuses showed that one was a complete hydatidiform mole with normal karyotype, five were trisomic, and all of the others were normal. In Japan, aberrations in children born after any kinds of ART diagnosed by attending pediatricians are to be reported to the central office of Japan Society of Obstetrics and Gynecology. As of today, St. Mother Clinic has not received any reports of medical problems in ROSI babies covered by this paper.

TABLE 1

Obstetrical history of 90 ROSI babies compared with babies born after TESE-ICSI.

Assisted fertilization	Cryopreservation of embryos	Total no. of women ^a	Total no. of treatment cycles	% of oocytes fertilized (fert/total)	% of oocytes cleaved (cleaved/total)	Total no. of transferred embryos	Total transfer cycles	No. (%) of recipients			Live offspring delivered	Total no. of live offspring
								Pregnant	Miscarried			
ROSI	No	721	2,290	55.3 (5,529/9,998)	52.7 (5,267/9,998)	3,091	1,471	80 (5.4)	35 (43.8)		45 (3.1)	48
	Yes	233	367	60.2 (2,603/4,326)	58.0 (2,508/4,326)	791	367	58 (15.8)	18 (31.0)		39 (10.6)	42
TESE-ICSI	No	154	214	32.7 (739/2,258)	31.3 (706/2,258)	194	127	20 (15.7)	7 (35.0)		13 (10.2)	13
	Yes	46	60	35.6 (383/1,076)	34.9 (375/1,076)	80	60	27 (45.0)	2 (7.4)		25 (41.6)	26

Note: The 90 ROSI babies include 14 previously reported (10). ICSI = intracytoplasmic sperm injection; ROSI = round spermatid injection; TESE = testicular sperm extraction.

^a About 80% of their husbands had been diagnosed as azoospermic in other clinics after micro-TESE before they came to the St. Mother Clinic, where another micro-TESE was performed to look for all kinds of spermatogenic cells, not just mature spermatozoa. Because of this, the number of TESE-ICSI performed in St. Mother Clinic was smaller than that of ROSI. Approximate proportions of ART performed in the St. Mother Clinic during the years of this investigation were: IVF 19.9%, ICSI using ejaculate spermatozoa 65.6%, ICSI using testicular spermatozoa and elongated spermatids 1.1%, ROSI 11.4%, and ICSI using epididymal spermatozoa 2.1%.

Tanaka. Round spermatid injection. Fertil Steril 2018.

TABLE 2

Crude means of anthropometric data at 1, 1.5, and 2 years of age.

Variable	Male							Female						
	Children born from round spermatid injection			Children born from natural conception			P value	Children born from round spermatid injection			Children born from natural conception			P value
	n	Mean	SD	n	Mean	SD		n	Mean	SD	n	Mean	SD	
Gestational duration (wk)	50	38.4	1.6	288	39.2	1.2	.002	34	38.2	1.8	250	39.0	1.4	.02
Birth weight (g)	50	3012.9	496.8	288	3109	376	.2	34	2841.9	402.4	250	2966.9	396.9	.09
Height at birth (cm)	50	49.1	2.6	288	49.1	1.8	.9	34	48.1	2.4	250	48.3	1.9	.7
Body mass index at birth (kg/m ²)	50	12.4	1.3	288	12.9	1.0	.02	34	12.3	1.3	250	12.7	1.2	.04
Age at 1-year measurement (mo)	22	12.2	1.2	126	12.3	1.0	.7	13	12.7	1.0	123	12.3	0.8	.1
Body weight at 1 y (g)	22	8455.5	2101	126	9314.5	970.5	.07	13	9015	1300.3	123	8721.4	847.8	.4
Height at 1 y (cm)	22	73.4	3.8	126	74.5	2.8	.2	13	72.9	2.4	123	72.8	2.3	.9
Body mass index at 1 y (kg/m ²)	22	15.8	3.6	126	16.8	1.1	.2	13	16.9	1.8	123	16.4	1.4	.3
Age at 1.5-year measurement (mo)	32	18.6	0.8	193	18.5	0.8	.4	23	18.6	0.8	176	18.4	0.8	.2
Body weight at 1.5 y (g)	32	9352.4	3231.9	193	10,666.5	980.2	.03	23	10,337.8	1141.1	176	10,014.9	964.5	.1
Height at 1.5 y (cm)	32	79.9	3.4	193	80.9	2.7	.08	23	79.6	3.0	176	79.4	2.5	.7
Body mass index at 1.5 y (kg/m ²)	32	14.7	4.9	193	16.3	1.3	.07	23	16.3	1.3	176	15.9	1.2	.1
Age at 2-year measurement (mo)	12	25.0	2.5	48	24.2	0.9	.3	8	25.9	3.5	32	24.3	0.8	.2
Body weight at 2 y (g)	12	10,517.9	3571.6	48	11,866.4	1097.2	.2	8	11,795	1301.5	32	11,223.1	1131.2	.2
Height at 2 y (cm)	12	85.5	4.3	48	85.7	2.8	.9	8	84.2	4.1	32	83.8	2.7	.7
Body mass index at 2 y (kg/m ²)	12	14.6	4.7	48	16.1	1.0	.3	8	16.6	1.4	32	16.0	1.3	.2

Tanaka. Round spermatid injection. *Fertil Steril* 2018.

Table 2 summarizes anthropometric data in ROSI and in naturally conceived babies. First, gestation was significantly shorter (male: $P=.002$; female: $P=.02$) in the ROSI group than in the natural group. Body mass index at birth was significantly smaller (male: $P=.02$; female: $P=.04$) in the ROSI group than in natural group, as was male birth weight ($P=.07$).

After controlling for confounding factors (such as birth order, gestational duration, sex of child, multiple pregnancy), the birth weight of ROSI babies was significantly greater than naturally conceived babies (102.26 g; $P=.02$; Supplemental Table 1, available online at www.fertstert.org). However, body weights at 12 and 18 months of age in the ROSI group were significantly lower than those of natural babies (473.66 g [$P=.02$] and 740.30 g [$P\leq.001$], respectively). Furthermore, body mass index at 18 months in the ROSI group was significantly lower than in the natural group (0.931 kg/m²; $P=.002$). Nevertheless, it should be noted that there was no statistical significant difference of childhood growth between the groups at 24 months of age. None of ROSI babies up to 2 years of age had signs of Prader-Willi syndrome, Angelman syndrome, Wiskott-Alrich syndrome, or any other unusual physical or mental aberrations.

Finally, to compare the cognitive development of babies born after ROSI and natural conception, questionnaires were sent to the parents of 90 babies born after ROSI and to the parents of 1,818 natural babies. Ninety-eight percent of the former and 37% of the latter responded to the survey (Supplemental Table 2, available online at www.fertstert.org). No statistical differences regarding their cognitive development were found, although a part of the response at 1 year of age in the ROSI group was significantly lower than in the natural group (Supplemental Table 3, available online at www.fertstert.org).

DISCUSSION

Although the success rate of ROSI is currently much lower than that of ICSI (Table 1), ROSI enabled at least some azoospermic men to have their own genetic offspring as they wanted.

There must be many reasons for the low efficiency of ROSI. It is possible that some of the round spermatids that we used for ROSI were in the process of degeneration. We need to be able to distinguish “young” spermatids from “senescent” ones. Because round spermatids and elongated spermatids are known to be sensitive to genotoxins (17), DNA strand breaks may accumulate in the cells that remain as round spermatids for an excessively long time (18). Furthermore, the possibility can not be ruled out that many of the round spermatids we used were incompletely imprinted even though it is known that, at least in mice, imprinting is complete at the spermatid stage (19) and even before meiosis (20). Further study is definitely needed to better identify spermatids competent to participate in normal embryo development.

One of reasons that many previous investigators failed to achieve pregnancy after ROSI could have been improper activation of oocytes. We can not expect good embryo development without good oocyte activation. In this study, we applied an electric current to oocytes before ROSI (10). We

used stainless steel electrodes, because this approach yielded much better oocyte activation and preimplantation development embryos than the use of platinum electrodes. The reason for this difference is not clear, but we found that far more electric current runs between two steel electrodes (chopstick type electrode) than platinum electrodes under the same voltage setting. Because phospholipase C zeta has been promoted as the intrinsic sperm-born oocyte-activating protein in mammals (21, 22) and injection of phospholipase C zeta RNA induces good activation of human oocytes (23), we must do more systematic work to determine if injection of such substances into oocytes yields better embryo development than electrostimulation.

The safety of any ART is a prime concern. Three of the 90 ROSI babies reported here had congenital aberrations at birth: a cleft lip and an omphalocele were successfully corrected without complications. A ventricular septal defect in one baby healed spontaneously. According to a survey by Hirahara (24), the incidences of these aberrations in the general Japanese population from 1997 to 2005 were: cleft lip, one in 1,724; ventricular septal defect, one in 575; and omphalocele, one in 2,564. Because of the small number of ROSI babies in our survey, we were unable to determine if there were statistical differences between ROSI and naturally conceived babies regarding the incidence of these congenital aberrations.

The body weight gains of ROSI babies were the same as those of naturally conceived babies except that at age 1.5 years ROSI boys were significantly lighter, but ROSI boys caught up by 2.0 years of age. Moreover, the cognitive development of the ROSI group was similar to that of the natural group except for the baby's response to parental greetings from 12 to 18 months.

Because this report is based on a rather small population of participants, more and longer-term studies are needed to assess the medical safety of ROSI. St. Mother Clinic (Atsushi Tanaka) and Aichi Medical University (Kohta Suzuki) plan to continue the follow-up study of the ROSI children reported here until the age of 6 years. Currently, about one-third of human azoospermia is thought to have genetic causes (25). Whether the remaining two-thirds of cases are genetic (dominant or recessive) or nongenetic must also be studied intensively.

Acknowledgments: The authors thank Dr. Atsuo Ogura (Riken, Tsukuba, Japan) for information of animal ROSI in general and Dr. Hiroyuki Tateno (Asahikawa Medical University, Asahikawa, Japan) for information about incidence and types of human congenital abnormalities in Japan. Special appreciation is expressed to Dr. J. Michael Bedford and Dr. Clairel O'Neill (Weill Cornell Medical College, New York) for reading the original manuscript and giving us invaluable advice and suggestions. The authors are indebted to Mr. Roberto Rodriguez for his help in English grammar.

REFERENCES

- Ogura A, Matsuda J, Yanagimachi R. Birth of normal young after electrofusion of mouse oocytes with round spermatids. *Proc Natl Acad Sci U S A* 1994;91:7460–2.
- Edwards RG, Tarin JJ, Dean N, Hirsch A, Tan SL. Are spermatid injections into human oocytes now mandatory? *Hum Reprod* 1994;9:2217–9.

3. Tesarik J, Mendoza C. Spermatid injection into human oocytes. I. Laboratory techniques and special features of zygote development. *Hum Reprod* 1996; 11:772–9.
4. Barak Y, Kogosowski A, Goldman S, Softer Y, Gonen Y, Tesarik J. Pregnancy and birth after transfer of embryos that developed from single-nucleated zygotes obtained by injection of round spermatids into oocytes. *Fert Steril* 1998;70:67–70.
5. Gianaroli L, Selman HA, Magli MC, Colpi G, Fortini D, Ferraretti AP. Birth of a healthy infant after conception with round spermatids isolated from cryopreserved testicular tissue. *Fert Steril* 1999;72:539–41.
6. Vanderzwalmen P, Nijs M, Stecher A, Zech H, Bertin G, Lejeune B, et al. Is there a future for spermatid injections? *Hum Reprod* 1998;13:71–84.
7. Silber SJ, Johnson L. Are spermatid injections of any clinical value? ROSNI and ROSI revisited. Round spermatid nucleus injection and round spermatid injection. *Hum Reprod* 1998;13:509–15.
8. Vloeberghs V, Verheyen G, Tournaye H. Intracytoplasmic spermatid injection and in vitro maturation: fact or fiction? *Clinics* 2013;68(Suppl 1):151–6.
9. Practice Committee of American Society for Reproductive Medicine; Practice Committee of Society for Assisted Reproductive Technology. Round spermatid nucleus injection (ROSNI). *Fert Steril* 2006;86(Suppl 1):S184–6.
10. Tanaka A, Nagayoshi M, Takemoto Y, Tanaka I, Kusunoki H, Watanabe S, et al. Fourteen babies born after round spermatid injection into human oocytes. *Proc Natl Acad Sci U S A* 2015;112:14629–34.
11. Schlegel PN. Causes of azoospermia and their management. *Reprod Fert Dev* 2004;16:56–72.
12. Esteves SC, Miyaoka R, Agarwal A. Sperm retrieval techniques for assisted reproduction. *Int Braz J Urol* 2011;17:570–83.
13. Tasdemir I, Tasdemir M, Tavukcuoglu S. Effect of pentoxifylline on immotile testicular spermatozoa. *J Assist Reprod Genet* 1998;15:90–2.
14. Nakamura Y. Maternal and child health handbook in Japan. *Jpn Med Assoc J* 2010;53:259–65.
15. Yoshida H, Kato N, Koyama T. Trends in maternal and child health (HCM) research in Japan: here and now, and beyond. *J Natl Inst Pub Health (Japan)* 2014;63:32–8.
16. Hashimoto K, Ogawa K, Horikawa R, Ikeda N, Kato K, Kamide A, et al. Gross motor function and general development of babies born after assisted reproductive technology. *J Obstet Gynaecol Res* 2016;42:266–72.
17. Ahmed EA, Scherthan H, de Rooij DG. DNA double strand break response and limited repair capacity in mouse elongated spermatids. *Int J Mol Sci* 2015;16:29923–35.
18. Jurisicova A, Lopes S, Mariano J, Oppedosano L, Casper RF, Varmuza S. DNA damage in round spermatids of mice with a targeted disruption of the Pp1c γ gene and in testicular biopsies of patients with nonobstructive azoospermia. *Mol Hum Reprod* 1999;5:323–30.
19. Shamanski FL, Kimura Y, Lavoie MC, Pedersen RA, Yanagimachi R. Status of genomic imprinting in mouse spermatids. *Hum Reprod* 1999;14: 1050–6.
20. Oakes CC, la Salle S, Smiraglia DJ, Robaire B, Traisler JM. Developmental acquisition of genome-wide DNA methylation occurs prior to meiosis in male germ cells. *Dev Biol* 2007;307:368–79.
21. Swann K, Lai FA. PLC ζ and the initiation of Ca²⁺ oscillations in fertilizing mammalian eggs. *Cell Calcium* 2013;53:55–62.
22. Swann K, Saunders CM, Rogers NT, Lai FA. PLC ζ : a sperm protein that triggers Ca²⁺ oscillations and egg activation in mammals. *Semin Cell Dev Biol* 2006;17:264–73.
23. Yamaguchi T, Ito M, Kuroda K, Takeda S, Tanaka A. The establishment of appropriate methods for egg-activation by human PLCZ1 RNA injection into human oocyte. *Cell Calcium* 2017;65:22–30.
24. Hirahara F. Birth defects monitoring systems—worldwide and Japan. *Acta Obst Gynecol Jpn* 2007;59:N246–50.
25. Hamada AJ, Esteves SC, Agarwal A. A comprehensive review of genetics and genetic testing in azoospermia. *Clinics* 2013;68:39–60.

Noventa niños nacidos después de inyección de espermátides redondas (ROSI) en ovocitos: encuesta de su desarrollo desde fecundación hasta los dos años de edad

Objetivo: Comparar el desarrollo físico y cognitivo de niños nacidos tras inyección de espermátides redondas (ROSI) con aquellos niños nacidos de una concepción natural.

Diseño: Eficiencia de ROSI utilizando espermatozoides testiculares realizadas en St. Mother Clinic. El desarrollo cognitivo y físico registrado por los padres en el Manual Madre-Hijo emitido por el gobierno fue revisado y verificado por pediatras adjuntos. Los datos incluyeron la ganancia de peso de los niños y la respuesta a los gestos y voces de los padres.

Escenario: Centro de reproducción asistida.

Pacientes: Un total de 721 hombres participaron en ROSI; se realizó seguimiento del desarrollo físico y cognitivo a 90 bebés de ROSI durante dos años. Los sujetos control fueron 1.818 bebés nacidos de una concepción natural.

Intervención: Recuperación quirúrgica de células espermáticas de los testículos; selección e inyección de espermátides redondas en los ovocitos; activación ovocitaria, cultivo embrionario in vitro y transferencia embrionaria a las madres.

Resultado Principal: El desarrollo físico y cognitivo de los niños nacidos tras ROSI (ejemplo: incremento del peso corporal, respuesta a los padres, y entendimiento y habla de lenguaje simple) comparado con bebés nacidos tras concepción natural.

Resultados: De los 90 niños nacidos tras ROSI, tres presentaron alteraciones congénitas al momento del nacimiento, que se corrigieron de forma espontánea (septos ventriculares) o quirúrgica (labio leporino y onfalocele). El desarrollo cognitivo y físico de los bebés ROSI fue similar al del grupo control.

Conclusiones: El desarrollo físico y cognitivo durante los dos primeros años de vida de los niños nacidos tras ROSI y de los concebidos de forma natural no presenta diferencias significativas.